



MC-2388

## TEST REPORT



Visit Id: R8872080

ANAND  
DIAGNOSTIC  
LABORATORY

A Neuberg ASSOCIATE

## Sample Source: Walkin

No.54, Anand Tower, Bowring Hospital Road, Shivajinagar, Bangalore-560001.

Name: MR MOHAMMED IMRAN

Age: 28 Year(s)

Gender: M

Contact No.: 8123356306

Ref. No.

Referring Dr.: DR. O

Registered: 25/10/2021 11:48

Reported: 26/10/2021 12:55

Report Status: Final

## CYTOLOGY TEST REPORT

## TESTICULAR FNAC

## IMPRESSION

Bilateral testes - Maturation arrest.

## CLINICAL DATA:

? Azoospermia. On examination - bilateral testicular volume - normal. Fructose status - Not available.

## REPORT:

Smears studied from both the testes are moderately cellular and show sertoli cells and germ cells. Germ cells show maturation to late spermatid. Sertoli cell index is 30%. Background shows proteinaceous material admixed with few RBCs. Smears are negative for granulomas or malignancy.

## SITE

Bilateral testes

## FNAC PROCEDURE DONE BY

Dr Rakshith

## DATE OF REPORTING :

26/10/2021

*FNAC is a screening tool and findings that are negative or positive should always be correlated and triaged with clinical examination and radiological or imaging findings including investigations such as mammography in the case of breast FNAC. Discordant findings in any of these will require further evaluation that may include biopsy and histopathological examination.*

2 Slide(s) Enclosed. Pl preserve them carefully.

----- End of CYTOLOGY TEST REPORT Report -----

Report Entered By  
Dr Priya Chandran

Seen By Pathologist

Reported By Pathologist

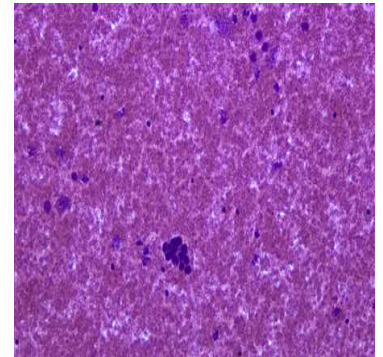
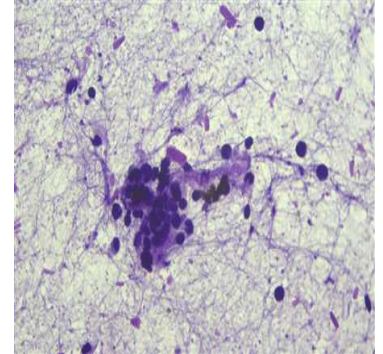
Dr. Anitha M

Dr. Priya Chandran

Pathologist

KMC NO.: - 66556

KMC NO. - 73865



**Department**  
CYTOLOGY TEST REPORT

**Time of Sample Collected**  
**Specimen**  
Glass slides

**Collected At**  
25/10/2021 12:04: